

# A new corporoplasty based on stratified structure of tunica albuginea for the treatment of congenital penile curvature – long-term results

Wojciech Perdzyński, Marek Adamek

Centre for Reconstructive Surgery of the Male Genito–Urinary Tract, Damian's Hospital, Warsaw, Poland

**Citation:** Perdzyński W, Adamek M. A new corporoplasty based on stratified structure of tunica albuginea for the treatment of congenital penile curvature – long-term results. Cent European J Urol. 2015; 68: 102-108.

## Article history

Submitted: Oct. 14, 2014

Accepted: Jan. 18, 2015

Published on-line:

March 13, 2015

## Corresponding author

Wojciech Perdzyński  
Centre for Reconstructive  
Surgery of the Male  
Genito–Urinary Tract  
Damian's Hospital  
46, Wałbrzyska Street  
02–739 Warsaw, Poland  
mobile phone  
+48 601 28 59 17  
perdzyński@perdzyński.pl

**Introduction** The aim of the study was to report long-term results of treatment of patients with congenital penile curvature (CPC) with a new corporoplasty based on stratified structure of tunica albuginea, in which corporal bodies are not opened.

**Material and methods** From October 2006 to September 2013, the authors operated on 111 adult men with CPC. Ventral curvature was detected in 65 patients, lateral in 34, and dorsal in 12. Skin was incised longitudinally on convex surface of curvature. In ventral curvature, dorsal neuro–vascular bundles (NVBs) were separated from tunica albuginea and elliptical fragments of external (longitudinal) layer of tunica were excised. The tunica was sutured with absorbable sutures, which invaginated the internal (transversal) layer of tunica. In dorsal curvature, excisions were performed on both sides of the urethra, in lateral curvature – on the convex penile surface.

**Results** Follow-up period was from 12 to 84 months. The penis was completely straight in 109 out of 111 patients. In 2 patients (1.8%) recurrent curvature of up to 20 degrees was detected. Redo surgery was done in one individual (0.9%) at patient's request. Glandular sensation loss or erectile dysfunction was not detected in any patient during the period of observation.

**Conclusions** A new operation for correction of CPC, which consists of excision of an elliptical fragment of the external layer of the tunica albuginea and plication of the internal layer gives good short and long-term results. Surgery done without penetrating the corpora cavernosa is minimally invasive, which diminishes the potential risk of complications, especially intra- and postoperative bleeding.

**Key Words:** penis <> congenital penile curvature <> tunica albuginea <> reconstructive surgery <> minimally-invasive operation

## INTRODUCTION

Congenital penile curvature (CPC) is a rare anomaly presenting with corporal deviation from the straight axis caused by a disproportion of tunica albuginea. The most common type is ventral curvature, followed by lateral and rarely dorsal. Sometimes it can be complex, joined with penile rotation or other anomalies. There are many different surgical techniques and all of them have a different success rate. For example, recurrence rate after tunical plication technique described by Essed–Schroeder

(E–S) is from 10 to 20% [1–5, 6]. After operations done using the 16-dot plication technique (16-dot PT) recurrence rate is 15% at a mean of 2.6 years of follow-up [7]. The main reasons for presence of these complications are suture loosening and breakage caused by erections or cut through of tied suture across the tunica. Postoperative problems arise because in the above mentioned methods, the smooth surface of tunica albuginea is only approximated by nonabsorbable sutures, and the final result is based solely on the sutures and not on the healing process itself [2–7, 8].

Another disadvantage of methods based on tunical plications is creation of protruding bulk (entire thickness of tunica albuginea) inside the cavernous cavity, which decreases its volume and compresses cavernosal tissue [4]. Excessive folding may also lead to decreased distal rigidity [9]. Discomfort or even pain from palpable knots of nonabsorbable sutures as well as narrowing or indentations are felt by up to one third of patients operated by tunical plication techniques [3, 4, 7]. On the other hand, low invasiveness without necessity of opening the cavernous cavity (1–7), and additionally – in 16-dot PT – without separation of dorsal neuro-vascular bundles (NVBs) from the tunica albuginea and short operative time are the main advantages of these techniques [7].

Corporoplasty described by Nesbit [10] or Yachia [11,12] allow for much better results (due to permanent fusion of tunical margins by healing process) in terms of recurrence (5 to 15%) but their invasiveness is greater because the corporal cavity is opened; underlying erectile tissue may be injured during tunical excision/incision and bleeding may occur. For this reason a tourniquet is often used during these procedures [3, 9–12]. If circulation within the penis is stopped for too long time (over 15 minutes?, over 30 minutes?), it may be harmful for erectile and sensory nerves as well as for erectile tissue. Postoperative haematoma caused by leakage through the sutured tunica albuginea is not rare after Nesbit operation [13].

For these reasons we tried to improve the technique of penile straightening in order to avoid disadvantages of the above mentioned techniques while still preserving their most important advantages such as low invasiveness [1–7] and reliable fusion of sutured margins of tunica [10, 11, 12]. Taking into account all of these factors, the authors developed a new, minimally invasive technique, based on the stratified structure of tunica albuginea, in which corpora cavernosa are not opened [14].

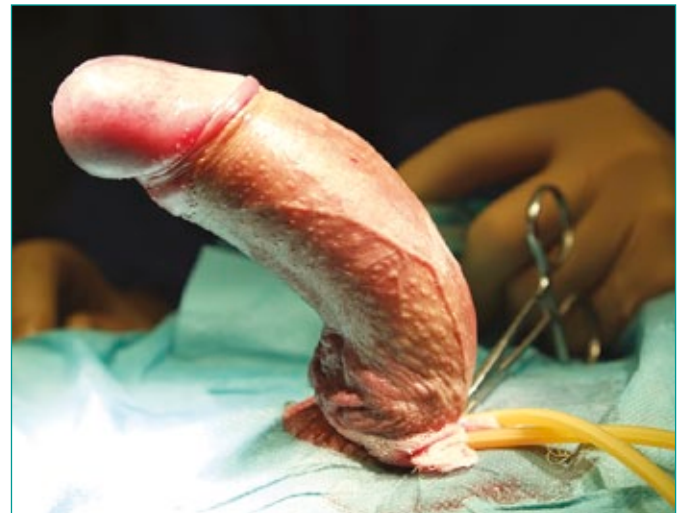## MATERIAL AND METHODS

From October 2006 to September 2013, the authors operated on 111 adult men with CPC aged from 18 to 53 years (mean – 24 years). All patients except one were younger than 34 years. The eldest patient in the study group noticed penile curvature in early adulthood but due to emotional problems for over 30 years delayed his decision to be operated. All patients were asked to provide a photograph of their penis in full erection. Degree of curvature which was qualified for correction was from 30 to 90 degrees (mean – 60 degrees). Ventral penile curvature was detected in 65 patients, lateral in 34, and dorsal

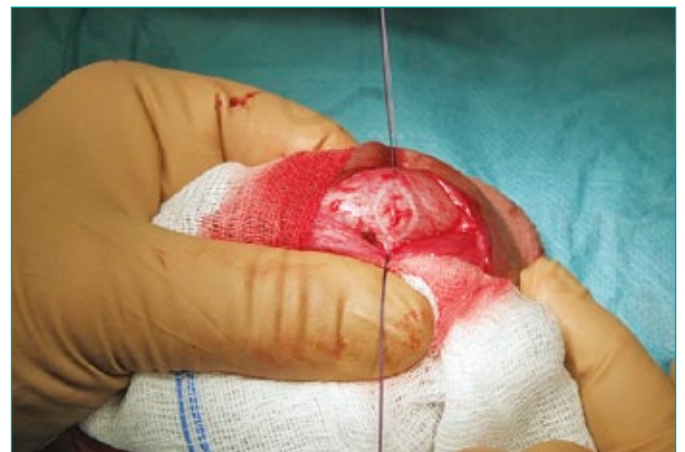in 12; in 24 patients curvature occurred in at least two planes (i.e. ventral and lateral, dorsal and lateral).

Anesthesia: injection into subarachnoidal space (lumbar part of spinal column) with 0,5% bupivacaine solution and intravenous sedation with 1% propofol emulsion.

Skin and tunica dartos were incised longitudinally on convex side of penis. Buck`s fascia was incised paraurethraly. After compressing the penile base with a tourniquet, artificial erection was induced by saline injection into cavernous cavity (Figure 1). The angle of curvature was estimated and a point of maximal angulation was marked by stay sutures. After releasing the tourniquet, a flaccid state – in which reconstruction is performed – is usually gained in a short time. To achieve support for incisions on the tunica albuginea, the penis is stretched by an assistant`s

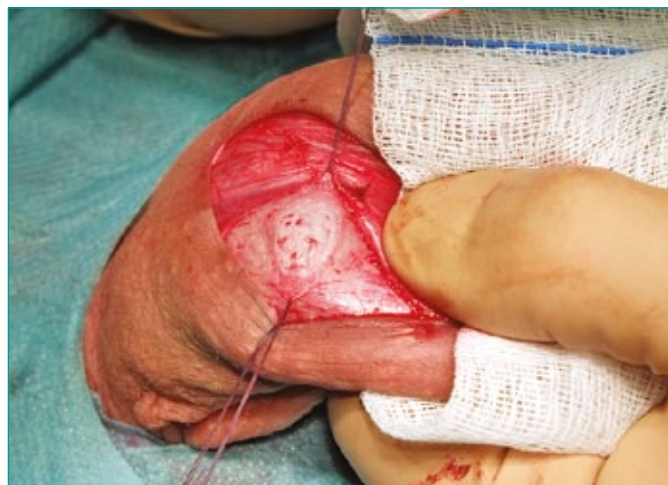

**Figure 1.** Intraoperative artificial erection: ventral penile curvature (70 degrees).

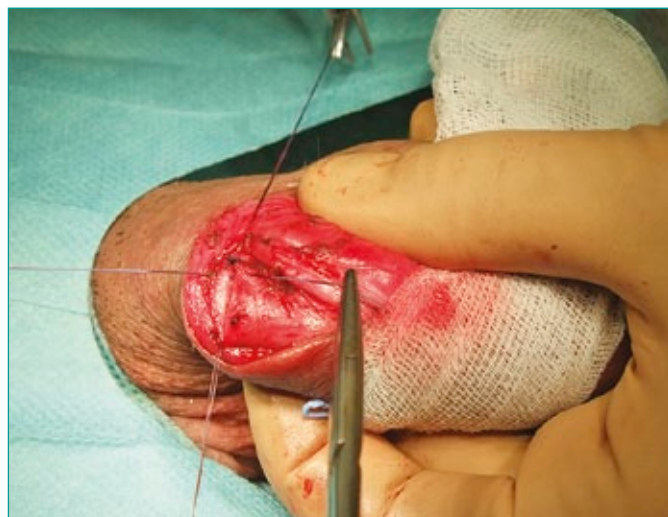

**Figure 2.** Elliptical incision of external (longitudinal) layer of tunica albuginea on dorsal penile surface.

index finger against the concave surface of the penis while his/her thumb is pressing the convex penile side. In ventral curvatures, dorsal NVBs are minimally mobilized longitudinally and elevated bilaterally together with Buck's fascia to the lateral margin of the deep dorsal vein groove. Elliptical incision of external (longitudinal) layer of tunica albuginea is done carefully between stay sutures (Figure 2), with preservation of the internal (transversal) layer. It is important to press delicately on the tunica with the knife during incision, which diminishes the possibility of tunical perforation into the corporal cavity. When the incision reaches the level of internal layer of tunica, excision of incised elliptical fragment

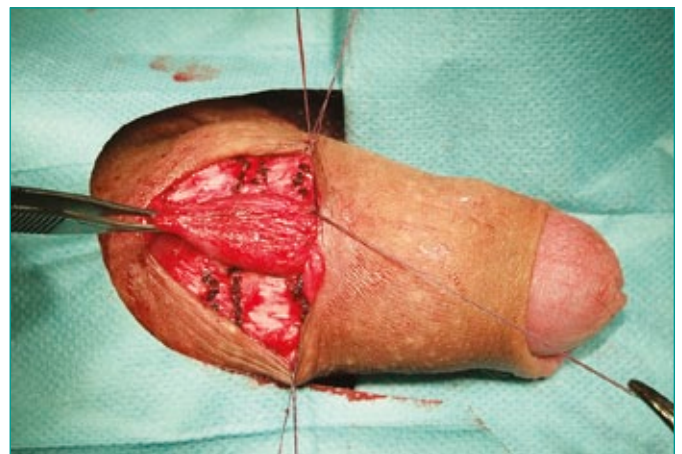


**Figure 3.** Incised fragment of external layer of tunica albuginea is excised, internal (transversal) layer is preserved. Above upper stay suture right NVB (medially moved) is seen. Clear colour difference between internal and external tunical layers is seen.

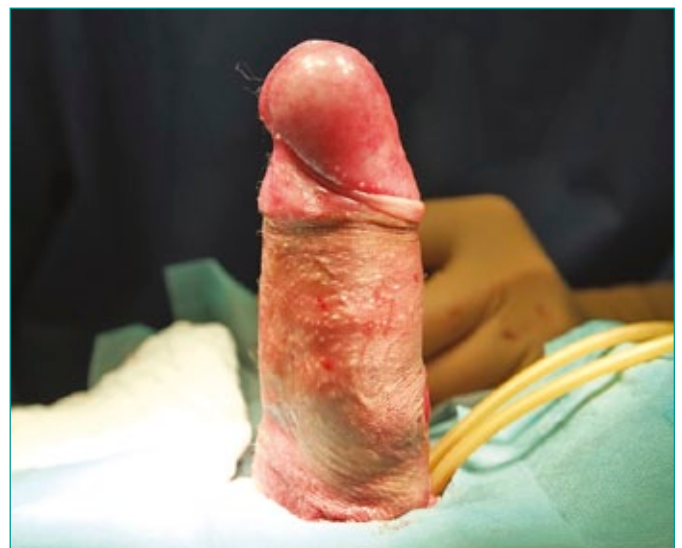

**Figure 4.** Margins of external layer of the tunica albuginea are sutured over the invaginated internal layer of tunica.

of external layer of tunica is done (Figure 3). Tunica albuginea is then sutured with 3-0 interrupted absorbable sutures passing through its full thickness, approximating the edges of external and invaginating internal layer (Figure 4). In all patients, straightening of the penis is checked by artificial erection. If curvature is still present, more incisions, excisions and plications are made (Figure 5) until curvature is corrected (Figure 6). Sutures placed on tunica albuginea are covered by deep and superficial fascias and by the skin (Figure 7). In patients with dorsal curvature, excisions were done on the ventral penile surface, symmetrically on both sides of the urethra. In lateral penile curvature, the same prin-

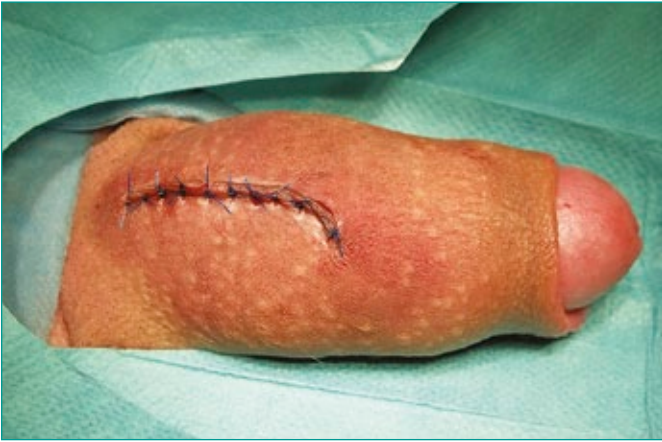

**Figure 5.** On dorsal penile surface, bilaterally 3 elliptical fragments of external layer of tunica were excised with invagination of internal layer by the sutures. Minimal elevation of NVBs both longitudinally and medially (to the lateral margin of deep dorsal vein groove).

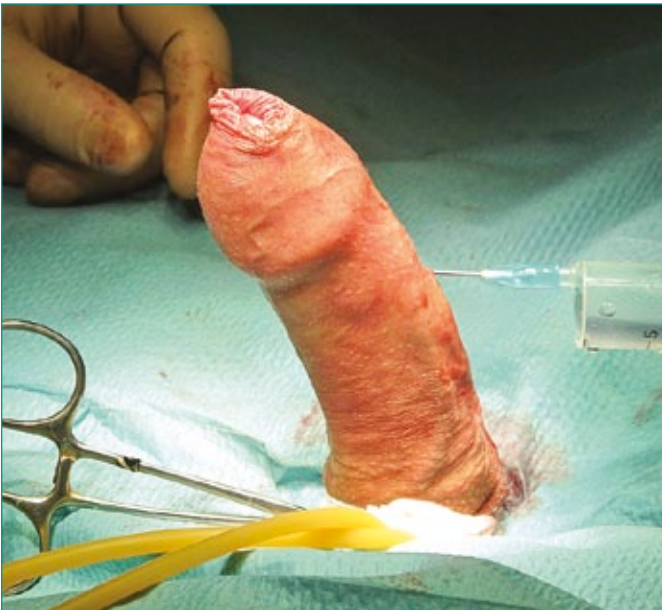

**Figure 6.** Intraoperative artificial erection: penis is straight.

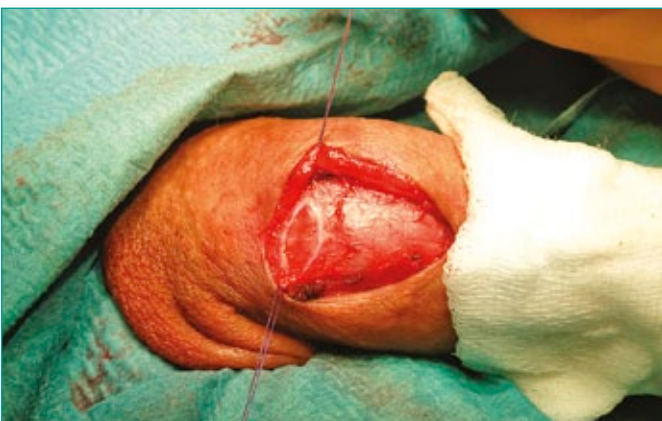



**Figure 7.** Operative wound is sutured.



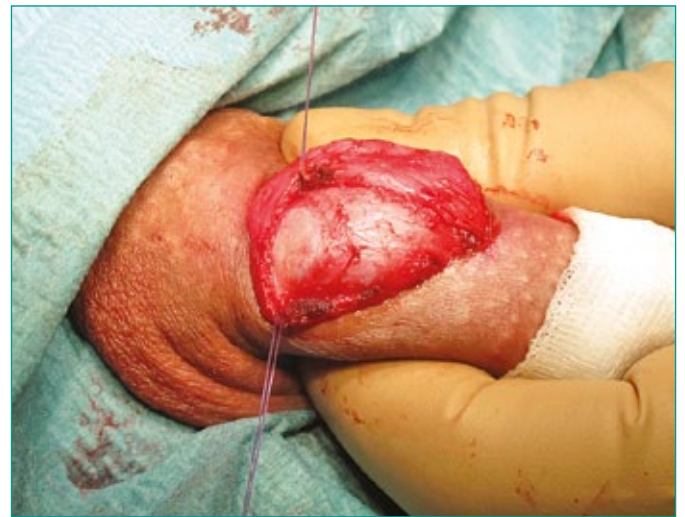**Figure 8.** Intraoperative artificial erection: lateral penile curvature (30 degrees, to the left).



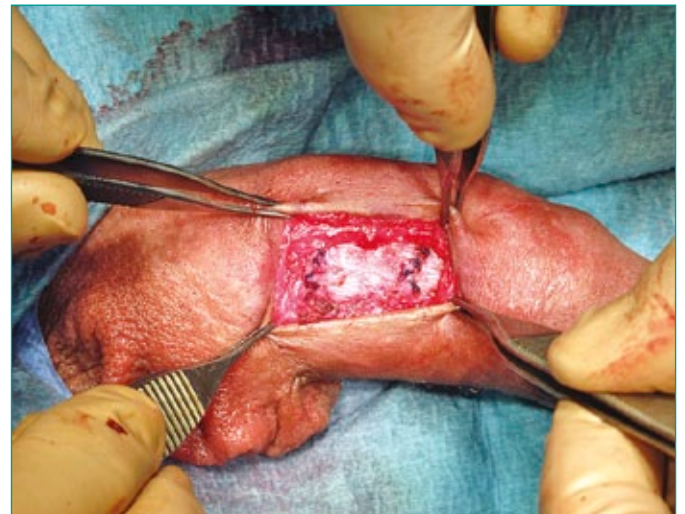
**Figure 9.** Elliptic incision of external layer of tunica albuginea on right lateral penile surface.

ciple was applied on the contralateral, convex side (Figure 8–13). In all patients, the penis was completely straightened during surgery. Urethral catheter was placed for one day. During the early postoperative period, transient penile oedema, usually mild, was detected. Patients were discharged 2 or 3 days after surgery. Antiandrogens (cyproterone) were given orally 3 days before and 21 days after surgery in order to prevent erections.

Follow-up examinations were done (with photography of penis in full erection) at 6 and 12 months after the operation. Afterwards, patients were asked to report if any change of penis shape during erection was observed.



**Figure 10.** Incised fragment of external layer of the tunica albuginea is excised, internal layer is preserved.



**Figure 11.** Margins of external layer of the tunica albuginea are sutured over invaginated internal layer of tunica. Minimal access to the tunica albuginea is seen.

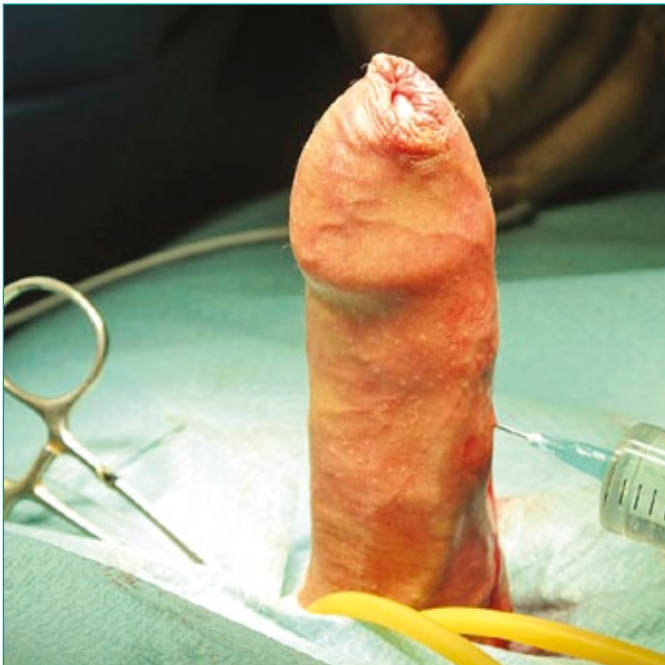

Figure 12. Intraoperative artificial erection: penis is straight.

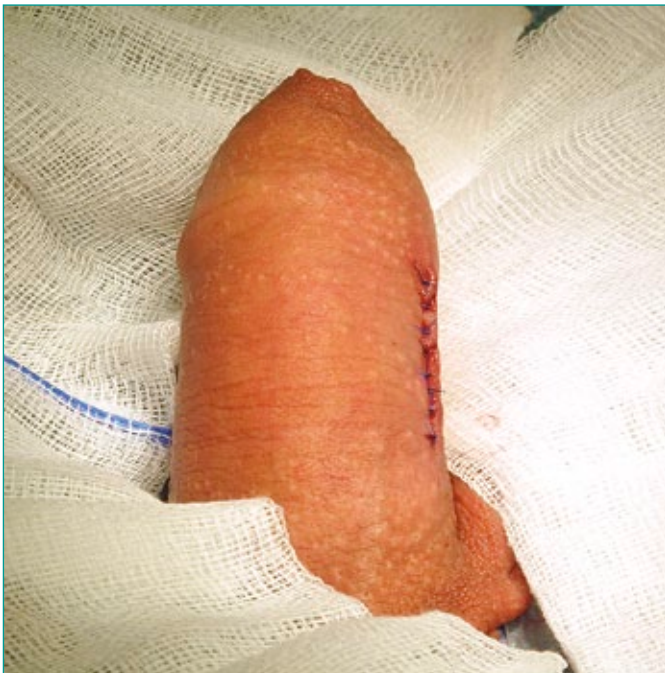

Figure 13. Operative wound is sutured.

## RESULTS

Follow-up was from 12 to 84 months (mean – 48 months). The penis was completely straight in 109 out of 111 patients. In 2 patients (1.8%) residual curvature up to 20 degrees was detected (primary curvature in these patients were 60 and 70 degrees, respecti-

Table 1. Summary of patient's data

Number of patients	111
Age	Mean – 24 years (range 18–53)
Degree of curvature	Mean – 60° (range 30°–90°)
Follow-up	1–7 years (mean – 4 years), 12–84 months (mean – 48 months)
Good result (straight penis)	109 patients – 98.2%
Residual curvature of up to 20°	2 patients – 1.8%
Reoperation (curvature of up to 20°)	1 patient – 0.9% (on patient's request)

vely). Redo surgery was done in one individual (0.9%), at patient's request, due to psychological reasons. Loss of glandular sensation or erectile dysfunction, was not detected in any patient during the observation period. None of the patients observed perceptible penile shortening. All of the patients started to feel great satisfaction from their sexual life and their self-confidence connected with this important part of life was much improved.

## DISCUSSION

Most authors correct CPC by shortening the longer, convex side of the penis and we used the same principle [5, 14, 16]. We tried to make use of advantages and to avoid disadvantages of the most commonly used techniques for penile straightening, with the goal to:

- avoid only approximation of intact and smooth tunica albuginea by the sutures [1–7],
- avoid opening of cavernous cavity, keeping in mind the possibility of bleeding and local injury of erectile tissue [2, 10, 11, 12],
- avoid using the tourniquet during tunical reconstruction with subsequent hypoxia (at least temporary) of penile nerves and erectile tissues [2, 10, 11, 12],
- take advantage of good healing of sutured margins of transected tunica [2, 10, 11, 12],
- take advantage of decreasing size of invaginated albuginea bulk into cavernous cavity [1–7].

Some authors noticed that simple invagination of the smooth, intact surface of tunica albuginea will not produce scarring strong enough to prevent recurrence [2–5]. Perovic et al. described a technique with numerous net-like incisions on tunica albuginea on the convex penile surface without penetrating corporal cavity creating a wound surface, which was infolded by the sutures [9]. Rehman modified the Nesbit operation by "shaving" some part of tunica albuginea and making plication of the shaved area [17] but this approach was not based on anatomy, i.e. the depth of "shaving" was not exactly determined.



Kuehhas and Egydio published their experience with superficial tunica albuginea excision in the treatment of ventral and ventro-lateral CPC using Egydio geometric principles [8]. They operated on 211 patients with very good results, detecting residual curvature of up to 30 degrees in 2 patients (0.9%) which were then reoperated. Eleven patients (5%) with residual curvature of up to 20 degrees needed no further treatment. It is interesting if asymmetric reconstruction of ventral curvature done only on one side of the dorsal penis surface, as proposed by Kuehhas and Egydio, does not result in axial twisting [8]. On the contrary, Belgrano et al. introduced asymmetric excisions of tunica albuginea for the treatment of penile torsions [18] gaining good results with their technique.

We used a technique of external tunica albuginea layer excision and plication of internal layer not only for ventral but also for lateral and dorsal curvatures. We think that for a reconstructive surgeon dealing with congenital penile curvatures, it is not difficult to find and to mark with stay sutures – during artificial erection – the top of the angle of curvature without using Egydio geometric principles, although they may be useful in some very complex cases.

Our approach is based on surgical differentiation of both tunical layers, which allows for precise excision of elliptical fragment of external layer of tunica containing longitudinally oriented fibers and plication only internal layer of tunica with transversally oriented fibers localized at the bottom of invaginated area [14, 19]. This diminishes compression of cavernosal vessels comparing to other plication techniques in which both tunical layers are invaginated [2, 3, 4, 7]. The other advantage of superficial tunical excision is creation of better healing surfaces which keeps the penis straight [8].

By increasing the number of elliptic incisions while decreasing their width, a better and more regular penile shape can be achieved. In this way, excessive penile indentation and formation of "dog ears" during erections can be avoided [2, 8]. In the original description of 16-dot PT, dots are placed 0,5 cm apart, that is why one suture (4 dots) invaginates 1,5 cm wide field of tunica, which may be responsible for indentations and for irregular penile shape after operation [7].

Many authors use vasoactive agents (prostaglandin E1 or papaverine) for obtaining artificial erection which is sustained during the time of corporoplasty [2, 7, 8, 9, 16, 20]. We produced artificial erection by saline injection into the cavernosal body only for assessing the degree of curvature and later for intraoperative control of progress of penile straightening. Usually after releasing the tourniquet, flaccidity can be restored very quickly [7, 15, 20] and

the next stages of our tunical repair were done on penis in its flaccid state. This is an important difference comparing to other techniques of penile reconstruction. To achieve support necessary for making tunical incisions/excisions the penis is stretched by an assistant's index finger against the concave surface of the penis while the distal part of the convex penile surface is pulled by a thumb. During placing and tying sutures, stretching of the penis is relieved. Sutures should be tied gently, with minimal tension, in order to prevent them from cutting through the tunica during surgery [7, 20]. We used 3/0 single absorbable sutures with the advantage of dividing tension among many sutures but with the drawback of temporary palpation of knots (usually for 2–3 months). It is also possible to place a continuous suture to avoid this, but in patients with strong erections a higher risk of recurrence may be anticipated (if suture rupture takes place). This modification is used in at least one center using our method (Djinovic R. – personal communication). Erections increase tension on sutured tunica albuginea and sexual intercourse adds some extra tension [15]. That is why most authors advice 2 months of abstinence from sexual intercourse [9, 11, 12, 15]. Younger patients, especially those <24 years old have a higher possibility of suture failure than older ones [15]. Antiandrogens may be used to decrease albugineal tension during erections, which may be harmful during the early post-operative period [8, 10, 16].

Most authors use a circumferential subcoronal incision and penile degloving for penile straightening [2, 9, 13, 15, 16, 20]. We use this approach only in patients with associated hypospadias or in those who want to be circumcised. Our preferred approach is through longitudinal skin and tunica dartos incisions over the convex surface of penis which decreases invasiveness (degloving is not necessary) as well as enables preservation of the foreskin [5, 7, 21]. In ventral curvatures authors prefer to perform local (as short and as narrow as possible) elevation instead of complete separation of both NVBs from tunica albuginea, which is our additional measure for decreasing intraoperative injury [22].

## CONCLUSIONS

This is a new surgical technique for correction of congenital penile curvature, which consists of excision of an elliptical fragment of the external layer and subsequent plication of the internal layer of tunica albuginea with good short and long-term results. Surgery done without penetrating of the

corpora cavernosa is minimally invasive, which diminish potential risk of complications, especially intra- and postoperative bleeding. There is no need for using a tourniquet during reconstruction, except for producing artificial erection necessary for initial assessment of curvature and then for estimation of the final result of correction. Familiarity with the stratified structure of tunica albuginea, as well as

a precise surgical technique are mandatory for successful application of this approach.

#### ACKNOWLEDGEMENTS

The authors would like to dedicate this paper to the memory of Professor Sava Perovic, a great mentor and friend of the first author. Additionally, the authors are grateful to Professor Terry W. Hensle and Dr. Rados Djinovic for revising the manuscript.

#### References

- Essed E and Schroder FH. New surgical treatment for Peyronie's disease. *Urology*. 1985; 25: 582–587.
- Nyirády P, Kelemen Z, Bánfi G, Rusz A, Majoros A, Romics I. Management of congenital penile curvature. *J Urol*. 2008; 179: 1495–1498.
- Schultheiss D, Meschi MR, Hagemann J, Truss MC, Stief ChG, Jonas U. Congenital and acquired penile deviation treated with Essed plication method. *Eur Urol*. 2000; 38: 167–171.
- Poulsen J and Kirkeby HJ. Treatment of penile curvature – a retrospective study of 175 patients operated with plication of the tunica albuginea or with the Nesbit procedure. *Br J Urol*. 1995; 75: 370–374.
- Friedrich MG, Evans D, Noldus J, Huland H. The correction of penile curvature with the Essed–Schroeder technique: a long-term follow-up assessing functional aspects and quality of life. *BJU Int*. 2000; 86: 1034–1038.
- Leonardo C, De Nunzio C, Michetti P, Tartaglia N, Tubaro A, De Dominicis C, Franco G. Plication corporoplasty versus Nesbit operation of congenital penile curvature. A long-term follow-up. *Int Urol Nephrol*. 2012; 44: 55–60.
- Gholami SS and Lue TF. Correction of penile curvature using the 16-dot plication technique: a review of 132 patients. *J Urol*. 2002; 167: 2066–2069.
- Kuehhas FE and Egydio PH. Superficial tunica albuginea excision, using geometric principles, for the correction of congenital penile curvature. *BJU Int*. 2012; 110: 949–953.
- Perovic SV, Djordjevic MLJ, Djakovic NG. A new approach to the treatment of penile curvature. *J Urol*. 1998; 160: 1123–1127.
- Nesbit RM. Congenital curvature of the phallus: report of three cases with description of corrective operation. *J Urol*. 1965; 93: 230–232.
- Yachia D. Modified corporoplasty for the treatment of penile curvature. *J Urol*. 1990; 143: 80–82.
- Yachia D. Our experience with penile deformations: incidence, operative techniques, and results. *J Androl*. 1994; 15: 63–68.
- Popken G, Wetterauer U, Schultze–Seemann W, Deckart AB, Sommerkamp H. A modified corporoplasty for treating congenital penile curvature and reducing incidence of palpable indurations. *BJU Int*. 1999; 83: 71–75.
- Perdzyński W. Excision of external layer of the tunica albuginea as an element of a new, little-invasive operative method for congenital penile curvature. Joint Meeting of the European (ESSM) and International (ISSM) Societies for Sexual Medicine, Brussels (Belgium), 7–11 December 2008. *J Sex Med*. 2008; suppl: 45–46. doi 10.13140/2.1.3960.6724
- Hsieh JT, Huang HE, Chen J, Chang HC, Liu SP. Modified plication of the tunica albuginea in treating congenital penile curvature. *BJU Int*. 2001; 88: 236–240.
- Chien GW, Abouseif SR. Corporeal plication for the treatment of congenital penile curvature. *J Urol*. 2003; 169: 599–602.
- Rehman J, Benet A, Minsky LS, Melman A. Results of surgical treatment for abnormal penile curvature: Peyronie's disease and congenital deviation by Nesbit plication (tunica shaving and plication). *J Urol*. 1997; 157: 1288–1291.
- Belgrano E, Liguori G, Trombetta C, Siracusano S. Correction of complex penile deformities by modified Nesbit procedure asymmetric tunica albuginea excision. *Eur Urol*. 2000; 38: 172–176.
- Perdzyński W, Adamek M. Late results after a new little-invasive corporoplasty based on stratified structure of tunica albuginea for the treatment of congenital penile curvature. 27th Annual Congress of European Association of Urology, Paris (France), 24–28 February 2012. [http://dx.doi.org/10.1016/S1569-9056\(12\)60806-9](http://dx.doi.org/10.1016/S1569-9056(12)60806-9).
- Baskin LS and Lue TF. The correction of congenital penile curvature in young men. *Br J Urol*. 1998; 81: 895–899.
- Perdzyński W, Adamek M. Excision of elliptic fragment of external layer of tunica albuginea as a new little-invasive method of treatment of congenital penile curvature. Vth International Meeting on Reconstructive Urology (IMORU), Hamburg (Germany), March 3–5, 2010. doi: 10.13140/2.1.2518.8805
- Perdzyński W, Adamek M. Ways to decrease invasiveness during operation for congenital penile curvature. 12<sup>th</sup> Congress of the European Society for Sexual Medicine, Lyon (France), 15–18, November, 2009. doi: 10.13140/2.1.3141.4725. ■